

# Matrix Associated Autologous Chondrocyte Transplantation of Patellar Cartilage Defects

Ploberger E\*, Fussenegger M\*\*, Meinhart J\*\*\*

\* Krankenhaus Ried, Austria, \*\*Krankenhaus Wels, Austria\*\*\*Krankenhaus Lainz, Vienna, Austria

## ABSTRACT

**Introduction:** Matrix associated autologous chondrocyte transplantation (MACT) has proven its clinical feasibility for the reconstruction of articular cartilage defects. However, only few clinical data are available for reconstructions of patellar cartilage defects. We summarize here the data of 13 patients whose patellar defects have been reconstructed by MACT.

**Patients and Methods:** Autologous chondrocyte cell cultures were established from small cartilage biopsies and were grown until sufficient cell numbers could be obtained. Cultivation took place in an accredited cell culture laboratory. Shortly before operation, the cultures were harvested and transferred to the operation theatre. After preparation of the defect, cells were mixed with a stabilized fibrin solution which was then allowed to polymerize on a collagen fleece. Before that, the fleece was trimmed to the shape of the defect. This cell-fibrin-collagen constructs could then easily be put into the defects where they tightly adhered to the surrounding tissue. The success of the transplantations was examined by using the knee evaluation score of the International Cartilage Repair Society (ICRS), by clinical and MRI examinations before operation and postoperatively at 6, 12 and 24 months.

**Results:** 13 patients with large patellar cartilage defects (mean defect size 7.8 +/-3.3 cm<sup>2</sup>) were treated by MACT based on stabilized chondrocyte-fibrin-collagen constructs. Median observation period was 9 months ranging from 2 to 24 months. During the observation period no transplant was lost and no secondary intervention was necessary. MR data demonstrated a progressive transformation of the chondrocyte-fibrin-collagen constructs to a mature tissue, producing a typical cartilage signal within one year. The subjective knee evaluation score (IKCD) was increased continuously after the operation and reached pre-accidental values.

**Summary:** MACT based on stabilized chondrocyte-fibrin-collagen constructs is a clinically feasible method. Additionally, it is safe and easy to use. Constructs adhere tightly to the surrounding tissue and can mature into cartilaginous tissue. The subjective knee evaluation score reached pre-accidental values, demonstrating a high level of patients satisfaction.

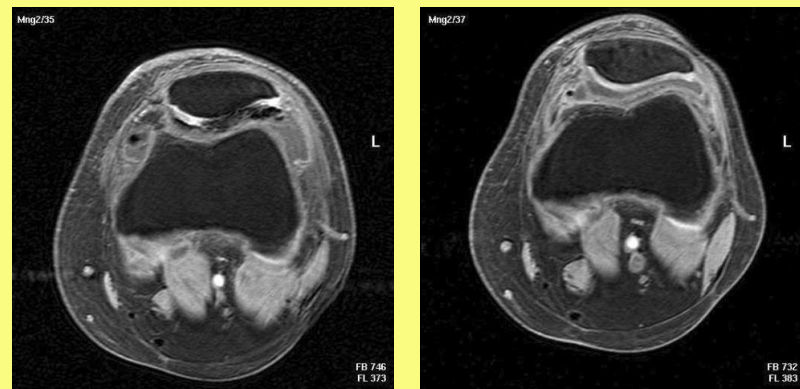


Fig2: MRI 4 days (left) and 4 months after reconstruction with stabilized fibrin-chondrocyte-collagen constructs

## INTRODUCTION

The matrix associated autologous chondrocyte transplantation (MACT) represents a further improvement of the autologous chondrocyte implantation (ACI), which has been clinically used for the first time 10 years ago<sup>1</sup>. Since then, several studies have proven its clinical efficacy. However, ACI inherits a number of limitations which are basically associated with its surgical complexity. Especially in the challenging region of the patella, ACI seems less effective, which is probably due to difficulties keeping the cells evenly distributed within the defect<sup>4</sup>. We therefore used a matrix associated chondrocyte transplantation system (igor chondro-systems, Wels, Austria).

## PATIENTS AND METHODS

Autologous chondrocyte cell cultures were established from small cartilage biopsies and were grown until sufficient cell numbers could be obtained. Cultivation took place in an accredited cell culture laboratory. Shortly before operation, the cultures were harvested and transferred to the operation theatre. After preparation of the defect, cells were mixed with a stabilized fibrin solution which was then allowed to polymerize on a collagen fleece. Before that, the fleece was trimmed to the shape of the defect. This cell-fibrin-collagen constructs could then easily be put into the defects where they tightly adhered to the surrounding tissue (Fig 1). The success of the transplantations was examined by using the knee evaluation score of the International Cartilage Repair Society (ICRS), by clinical and MRI examinations before operation and postoperatively at 6, 12 and 24 months.

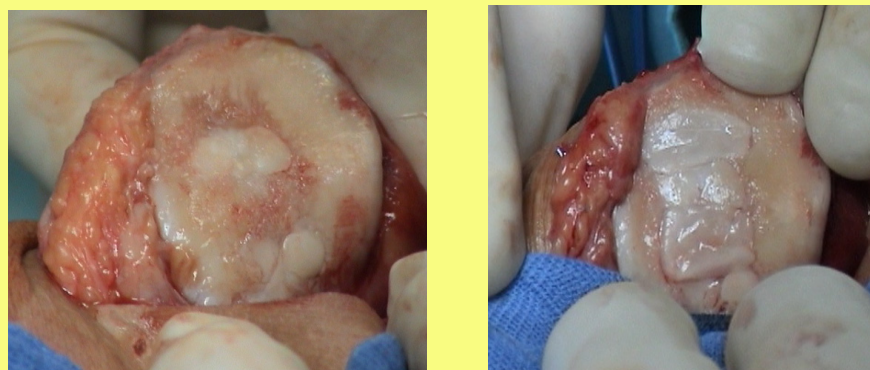


Fig1: A defect after preparation (left) and after filling a with stabilized fibrin-chondrocyte-collagen construct

## RESULTS

13 patients with large patellar cartilage defects (mean defect size 7.8 +/-3.3 cm<sup>2</sup>) were treated by MACT based on stabilized chondrocyte-fibrin-collagen constructs. The mean age of the patients was 37.4±5.3 years and the median observation period was 9 months ranging from 2 to 24 months. During the observation period no transplant was lost and no secondary intervention was necessary. MR data demonstrated a progressive transformation of the chondrocyte-fibrin-collagen constructs to a mature tissue, producing a typical cartilage signal within one year (Fig 2).

## RESULTS (cont)

The subjective knee evaluation score (IKCD) increased continuously after the operation. All patients evaluated their inflicted knee better or at least equal at the second evaluation at 24 months than at the first after after one year (Fig 3). Also the Activity index increased significantly over time and reached preaccidental values (Fig 4), expressing a high level of patients satisfaction with their reconstructed knee.

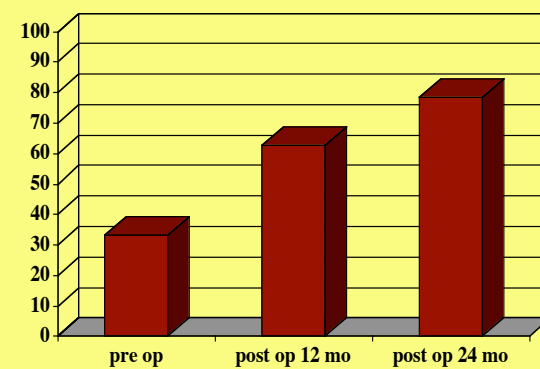


Fig3: The subjective knee evaluation (IKCD) index increased over time

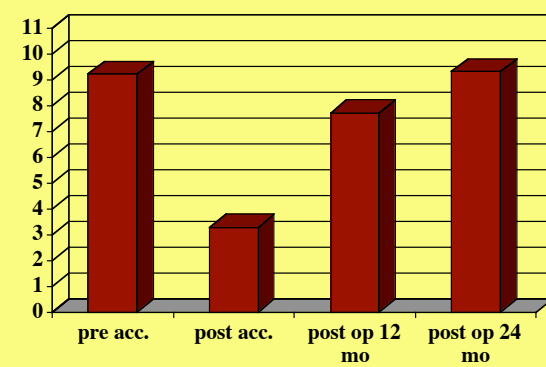


Fig 4: The activity index increased over time, reaching preaccidental values

## DISCUSSION

Autologous chondrocyte transplantation (ACT) has proven its clinical feasibility, especially for defects of the condyls. Defects of the patella showed less favourable results<sup>4</sup>. Indeed, ACI inherits a number of limitations which are especially critical for applications on the patella. We therefore looked for a method which facilitates the filling of the patellar defects with chondrocytes. The variant of the matrix associated autologous chondrocyte transplantation (MACT) we used has several advantages as compared to ACT and other MACT applications. Firstly, it does not need a membrane to cover the defect, which is surgically elaborate. Secondly, it uses a stabilized ultra fine fibrin meshwork for an even distribution of the cells within the constructs. Additionally, this meshwork provides the cells with an invironment where the cells are hold in place in a rounded shape, a physiologic prerequisite for the production of cartilage specific extracellular matrix components<sup>5,6</sup>. Thirdly, the collagen sponge gives the constructs the structure for easy handling and exact defect size. Fourthly, the components are mixed together freshly right after defect partation, allowing to adapt the constructs to any defect situation, including number of needed constructs and hight of the constructs. Together, these features allow a quick and easy defect reconstruction even at the challenging region of the patella. We did not loose a transplant sofar, and all MRI controls showed a gradual maturation of the constructs into cartilage. Moreover, all patients showed an increasing IKCD self evaluation index. From our experience we can recommend MACT for the reconstruction of patellar cartilage defects.

## LITERATURE

1. Britberg M, Lindahl A, Nilsson A, Ohlsson C, Isaksson O, Pettersson I. Treatment of deep cartilage defects of the knee with autologous chondrocyte transplantation. N Eng J Med 1994;331:889-95
2. Bentley G, Biant LC, Carrington RWJ, Akmal M, Goldberg A, Williams AM, Skinner JA, Pringle J. A prospective, randomised comparison of autologous chondrocyte implantation versus mosaicplasty for osteochondral defects in the knee. J Bone Joint Surg (Br) 2003;85-B:223-30
3. Knutsen G, Engebreetsen L, Ludvigsen TC, Drogset JO, Gronqvist T, Solheim E, Strand T, Roberts S, Isakson V, Johansen O. Autologous chondrocyte implantation compared with microfracture in the knee. J Bone Joint Surg 2004;86-A:455-64
4. Lindahl A, Britberg M, Peterson L. Cartilage repair with chondrocytes: clinical and cellular aspects. Novartis Found Symp 2003;249:175-86
5. Meinhart J, Fussenegger M, Hoehling W. Stabilisation of fibrin-chondrocyte constructs for cartilage reconstruction Ann Plast Surg 42:673-8, 1999
6. Fussenegger M, Meinhart J, Hobling W, Kullich W, Funk S, Bernatzky G. Stabilized autologous fibrin-chondrocyte constructs for cartilage repair in vivo. Ann Plast Surg 51:493-498, 2003